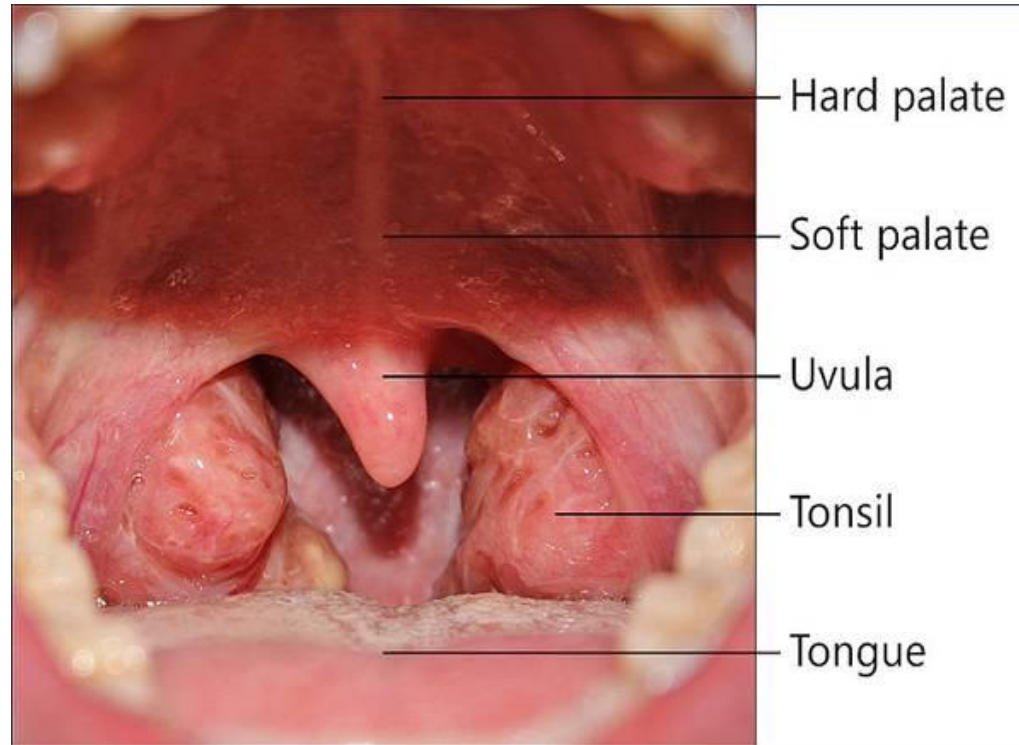


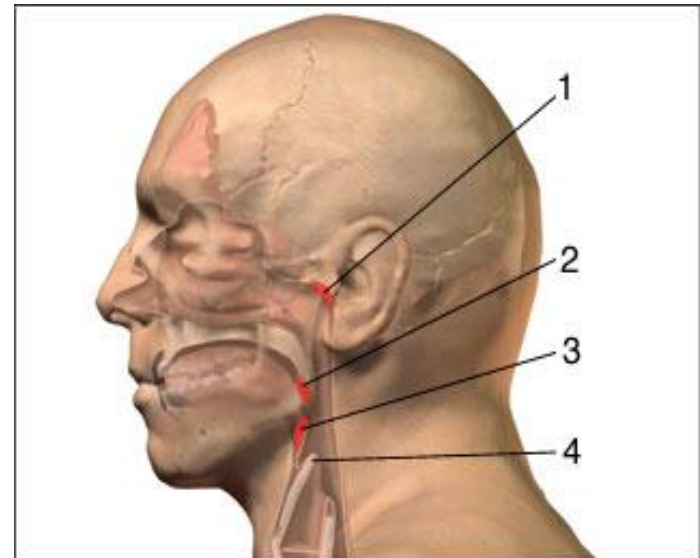
Tonsillectomy – Pros and cons



By : Tal Berger – Internal B ward

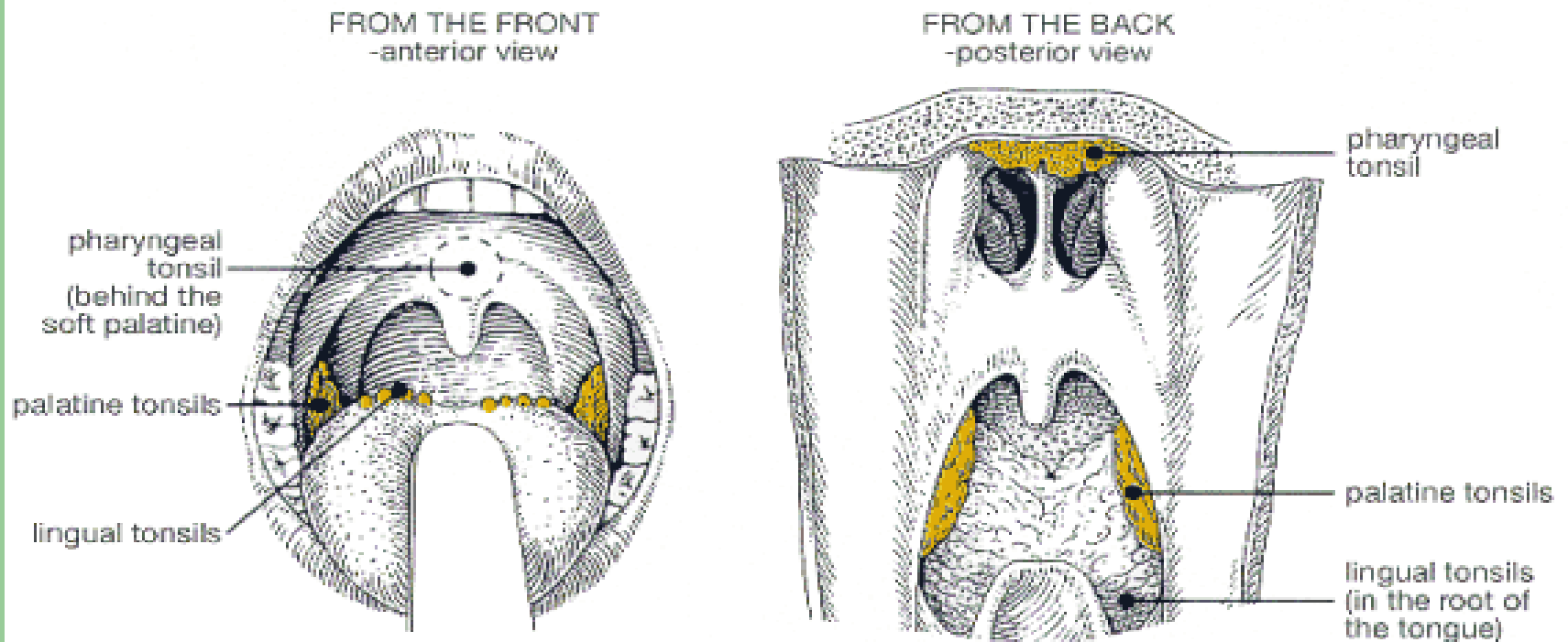
Once upon a time in Anatomy...

- **Palatine tonsil (“the tonsils”)** – located superior and anterior to the superior cervical ganglion, anterior to the vertebral junction C1 and C2 (2).
- **Pharyngeal tonsil (“The adenoids”)** – located in the roof of the mouth (1).
- **Laryngeal tonsil** – located close to the vocal cords (3).
- **Tubal tonsil** – located inside the Eustachian tube.
- **Lingual tonsil** – visible on the upper surface of the tongue.



One ring to rule them all

- Those 5 lymphatic organs are considered as one integral system – **Waldeyer's ring**



Function of the tonsils

- Nature never puts anything as a waste...
- 1. Monitor quality of air, water, food which enter the body.
- 2. Take part in the body immunity(forming lymphocytes, trapping and destroying bacteria).
- 3. Serve as a red light indicating infection in the body, when it becomes swollen and red.

Indication for tonsillectomy

- Upper airway obstruction (because of enlarged tonsils, due to infection or allergy) – sleep apnea, snoring
- 3-5 bacterial tonsillar infection over 3-5 years. usually occur due to infection with a beta – hemolytic Streptococcus (“Strep throat”).
- Chronic tonsillitis not responding to medical management.
- More than 7 episodes of tonsillitis a year.
- Suspicion of Tonsillar malignancy.
- Peritonsillar Abscess (Quinsy tonsillectomy).

Complications of Tonsillectomy

- Bleeding.
- Subsequent / concurrent ear/sinus infection.
- Permanent change in voice or nasal regurgitation.
- Nasopharyngeal stenosis
- An increase risk of Hodgkin lymphoma.

The connection between Hodgkin lymphoma and tonsillectomy

- A nationwide cohort study was made by the Department of Epidemiology Research, Statens Serum Institut, Copenhagen, Denmark.
- It included all Danish residents between the years 1977-2001.
- From 2988 HL patients, 58 were tonsillectomized (most with preceding tonsillitis) and 14 were diagnosed with only tonsillitis more than one year before HL diagnosis.
- Tonsillectomy was associated with a significantly increased HL risk in persons under 15 years of age as follows: 1-4 years after tonsillectomy, relative risk (RR)=3.9 (CI 95 % 1.4-11, n=4); > 5 years after tonsillectomy RR=3.5 (CI 95% 1.4-8.5, n=5).

On the other hand

- In contrast, 1-4 years after a hospital diagnosis of tonsillitis without subsequent tonsillectomy an increased HL risk was found in persons 15 years or above as follows: 15-34 years of age at HL diagnosis, RR=3.5 (CI 95 % 1.6-7.7, n=6) and 35+ years, RR=5.9 (CI 95% 2.2-16, n=4).

Conclusion

- An increased HL risk was found both after tonsillectomy and after an isolated diagnosis of tonsillitis. These results might suggest that tonsillitis is also a risk factor for HL and not as previously reported only the surgical removal of the tonsils.

Thank you

