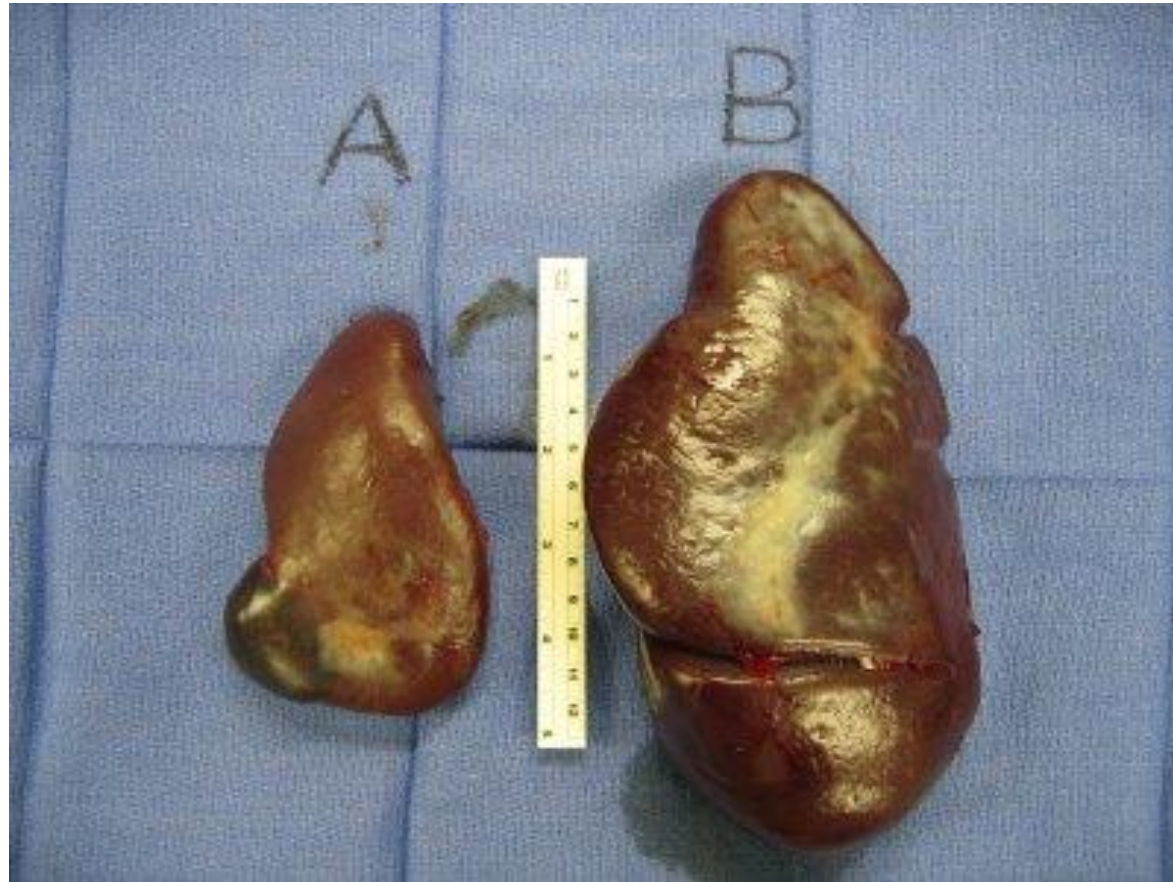

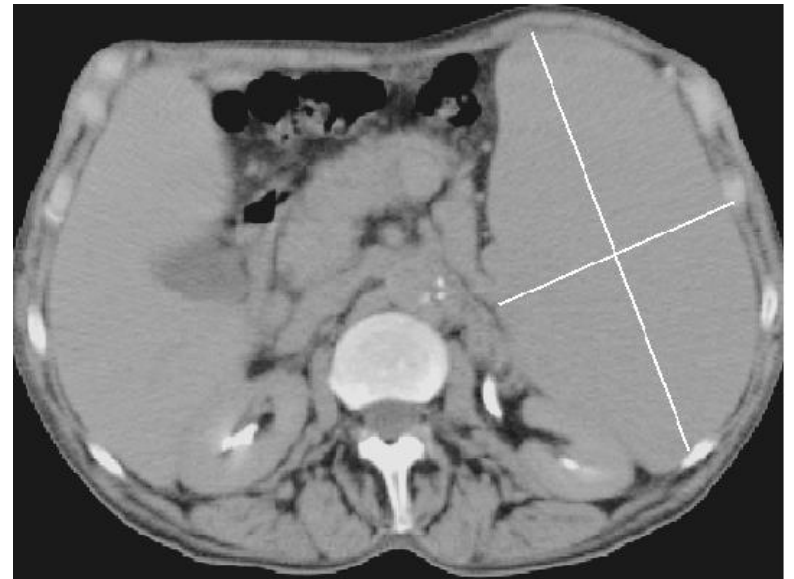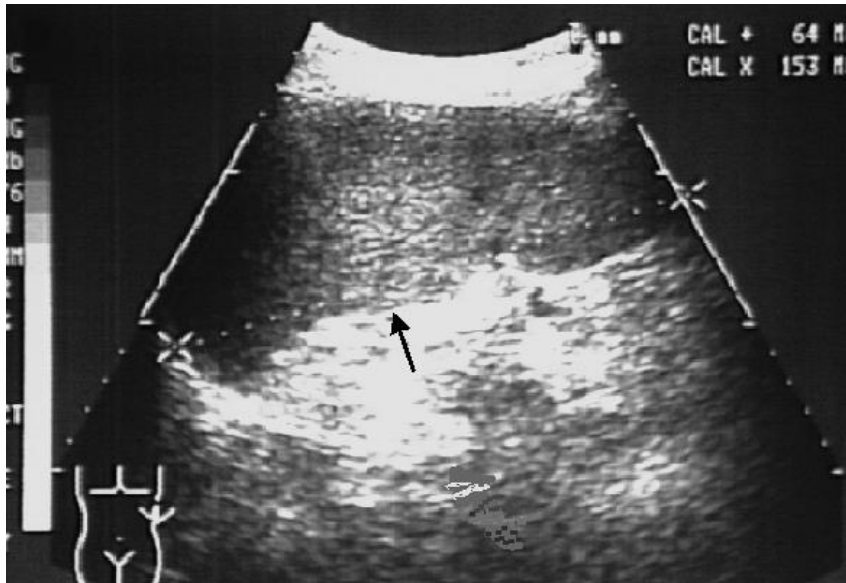
DD of a Firm Enlarged Spleen



DD of a Firm Enlarged Spleen

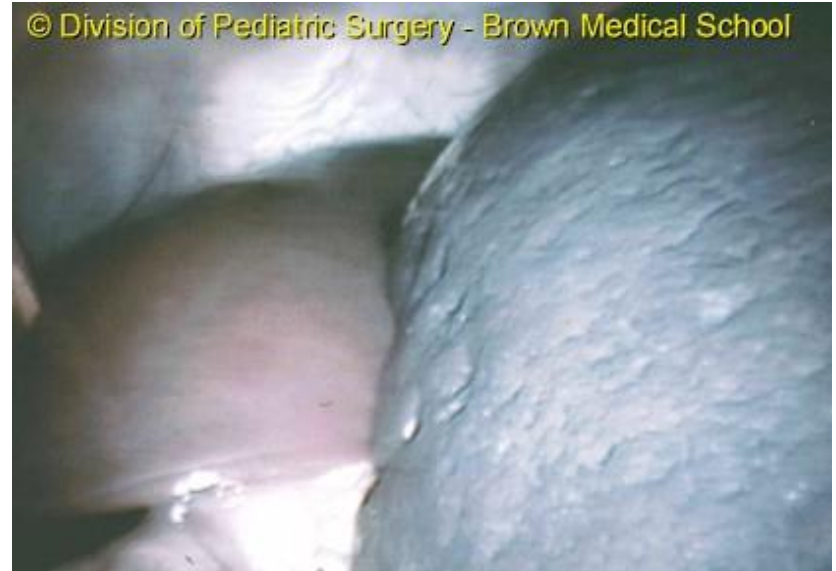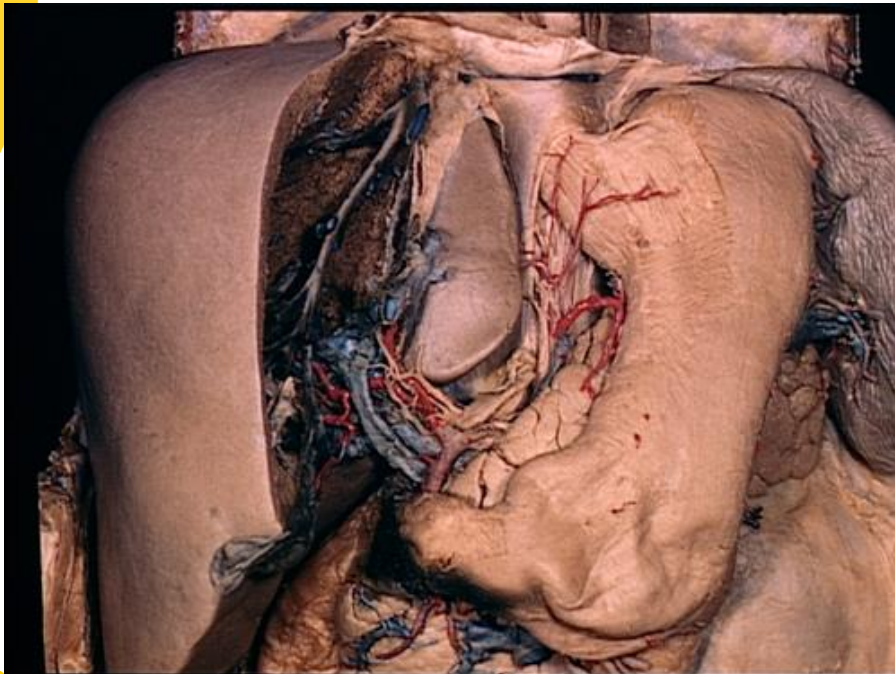
- Myelofibrosis
- Malaria
- Portal HTN
- Hemolytic Anemia
- Hereditary Spherocytosis
- Thalassemia

Imaging

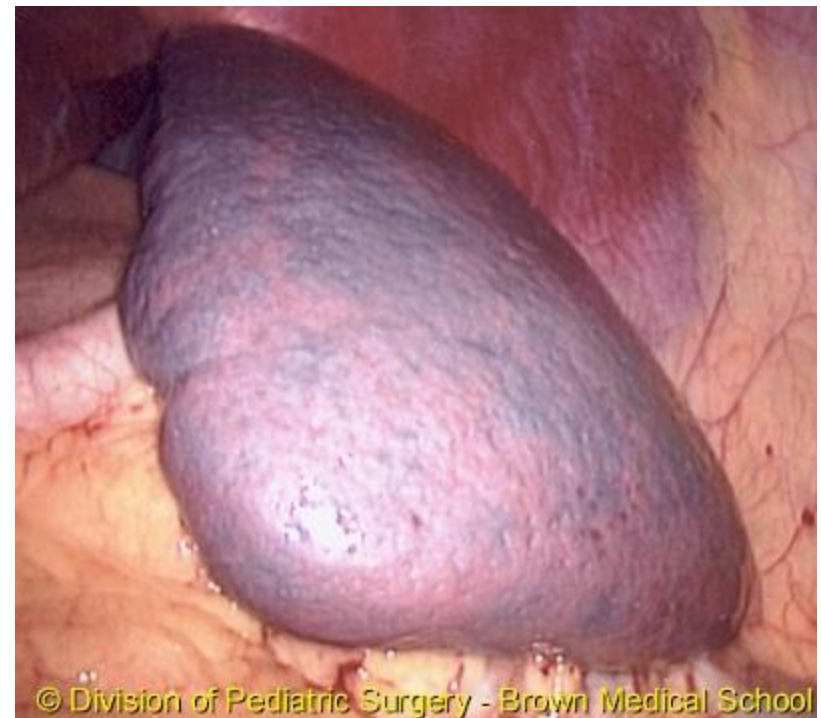
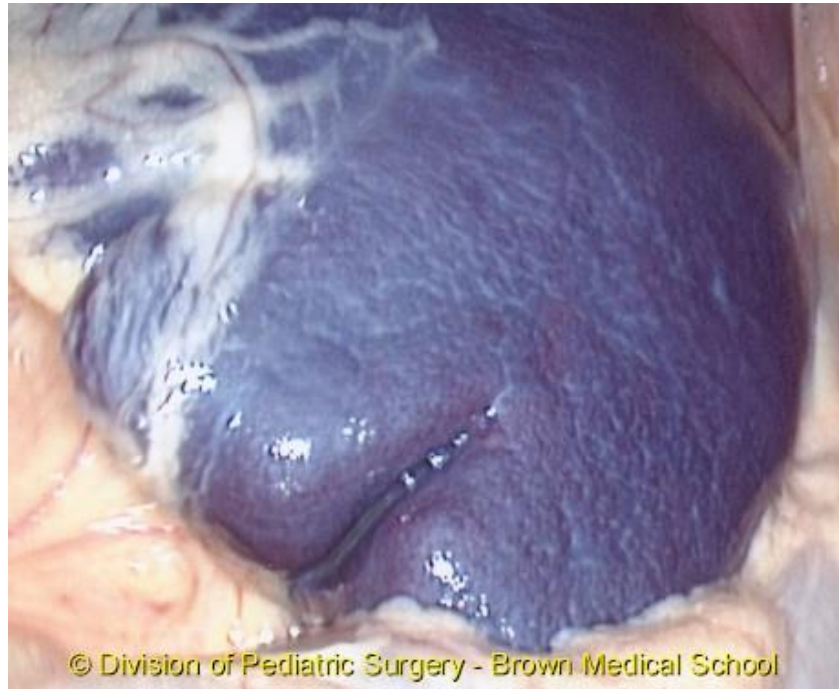
Splenomegaly

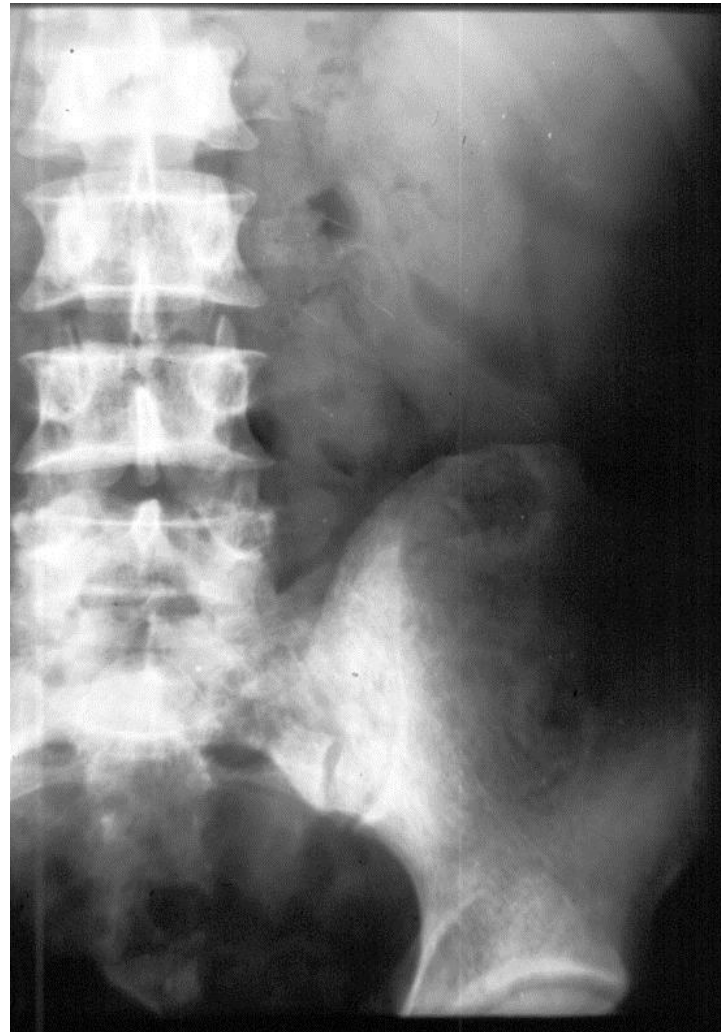
© Division of Pediatric Surgery - Brown Medical School



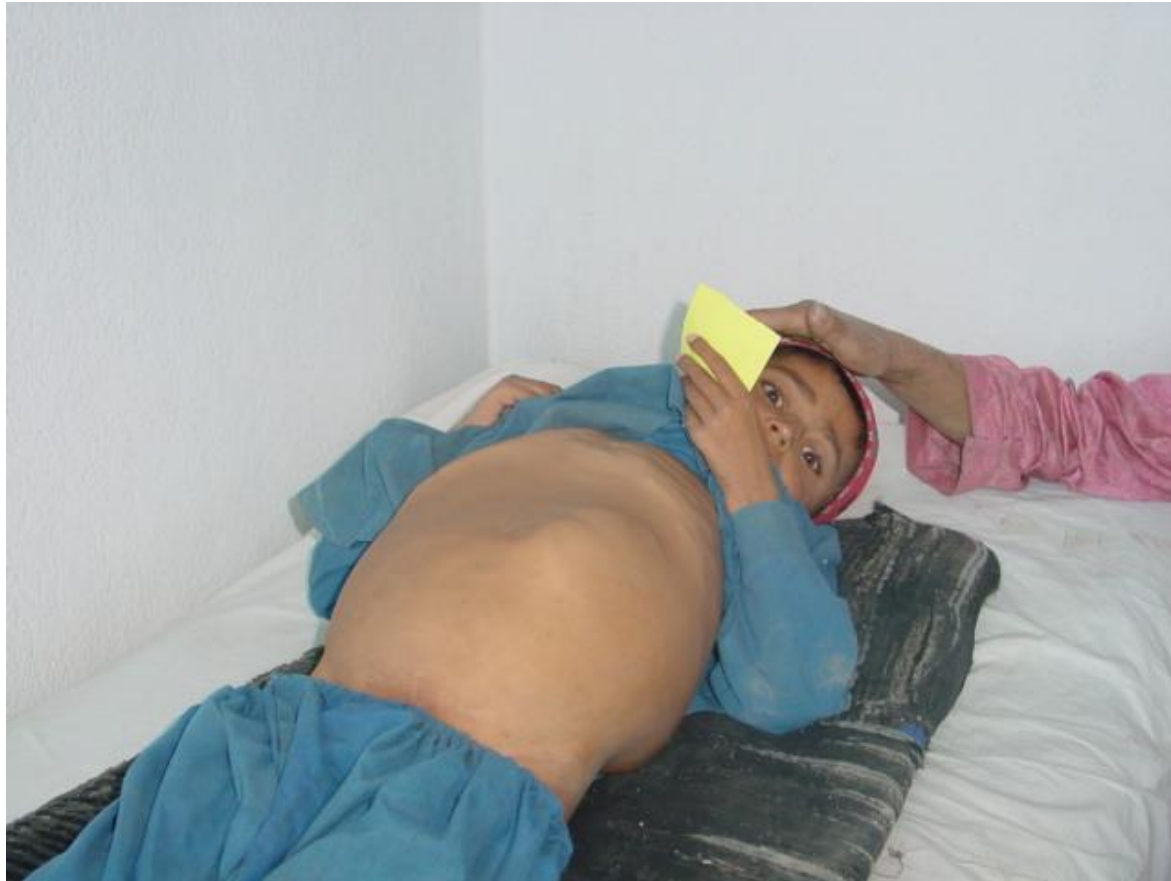Hereditary Spherocytosis



Myelofibrosis



Malaria



No Relevance at All but Interesting – Enlarged Thyroid

