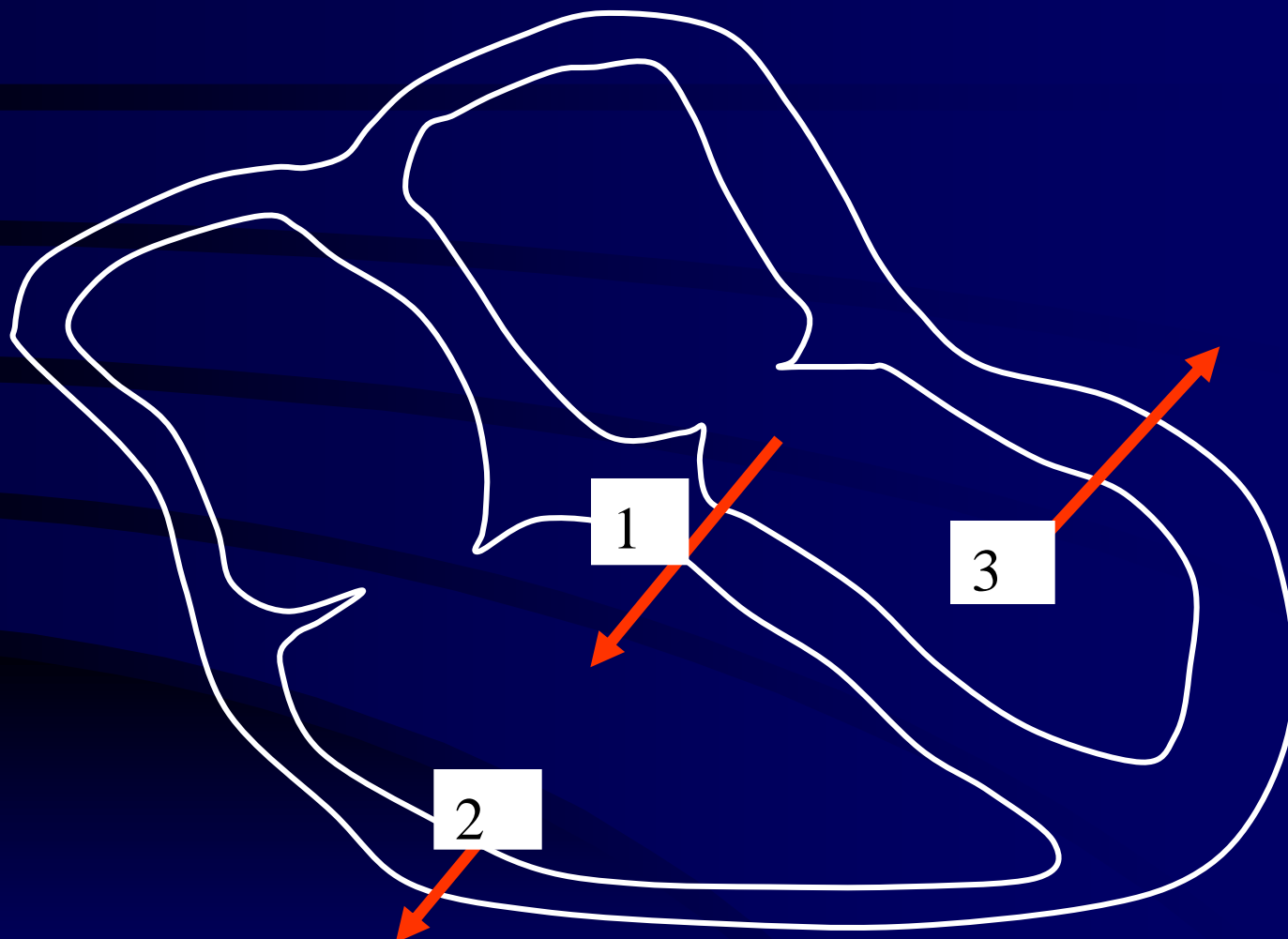


Bundle Branch Block

Phases of Activation

- Phase 1 - septal depolarisation occurring from left to right, 1st and alone
- Phase 2 & 3 - depolarisation of free wall of left & right ventricles, occurring together



RV

RV

IVS

IVS

LV

LV



V1

V2

V3

V4

V5

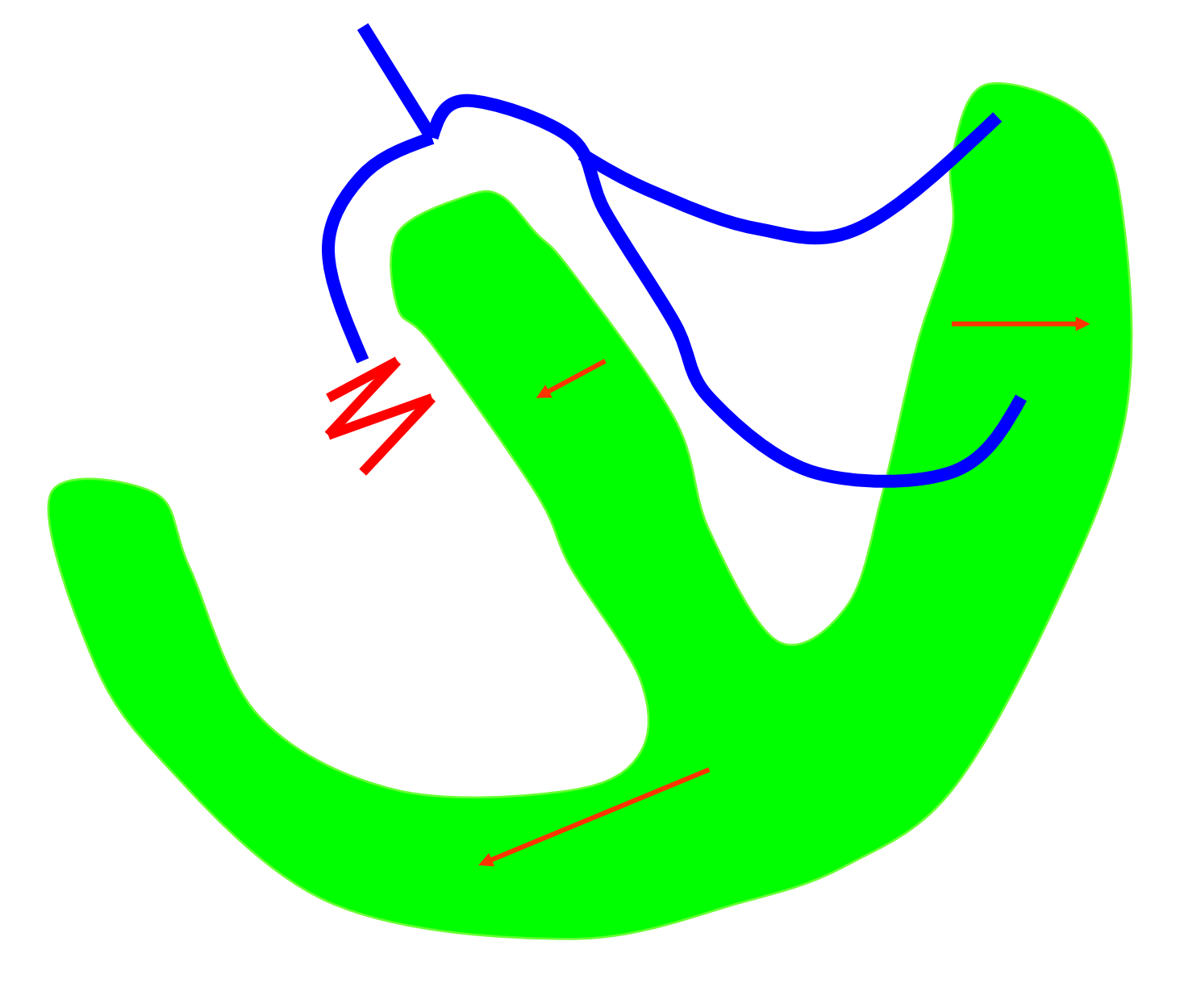
V6

Bundle Branch Block

- A delay of conduction in either of the bundle branches.

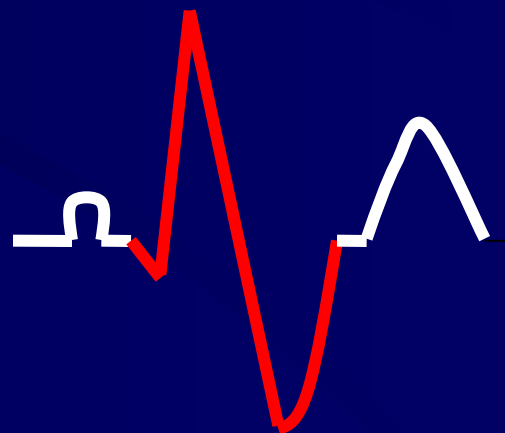
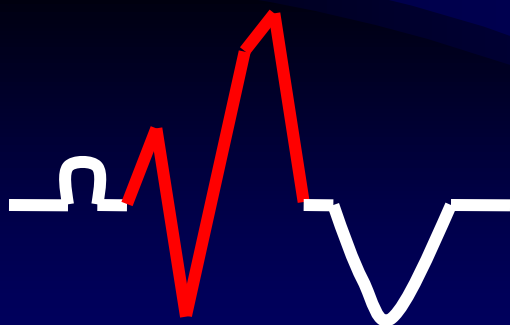
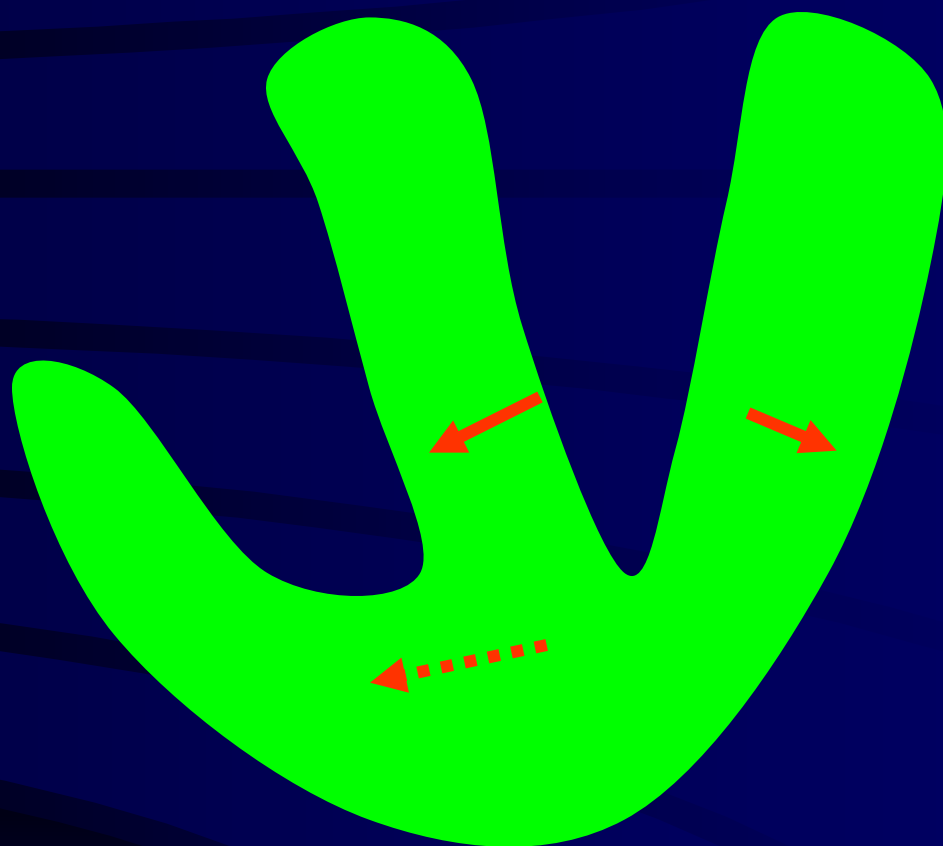
Right Bundle Branch Block

- In RBBB the right ventricle is stimulated by the impulse from the left ventricle.



Phases of Activation

- The septum depolarises from left to right as normal. (1)
- The left ventricle is depolarised as normal. (2)
- Finally the right ventricle is depolarised late (wide) in an anterior movement. (3)
- Resulting QRS is wide due to slow conduction through myocardial cells.



ECG criteria for RBBB

- (1) QRS duration exceeds 0.12 seconds
- (2) RSR complex in V1
- (3) Delayed S wave in I, V5, V6
- (4) ST/T must be opposite in direction to the terminal QRS
(is secondary to the block and does not predispose primary ST/T changes)

RBBB & MI

- If abnormal Q waves are present they will not be masked by the BBB pattern.
- This is because there is no alteration of the initial part of the complex RS (in V1) and abnormal Q waves can still be seen.

Significance of RBBB

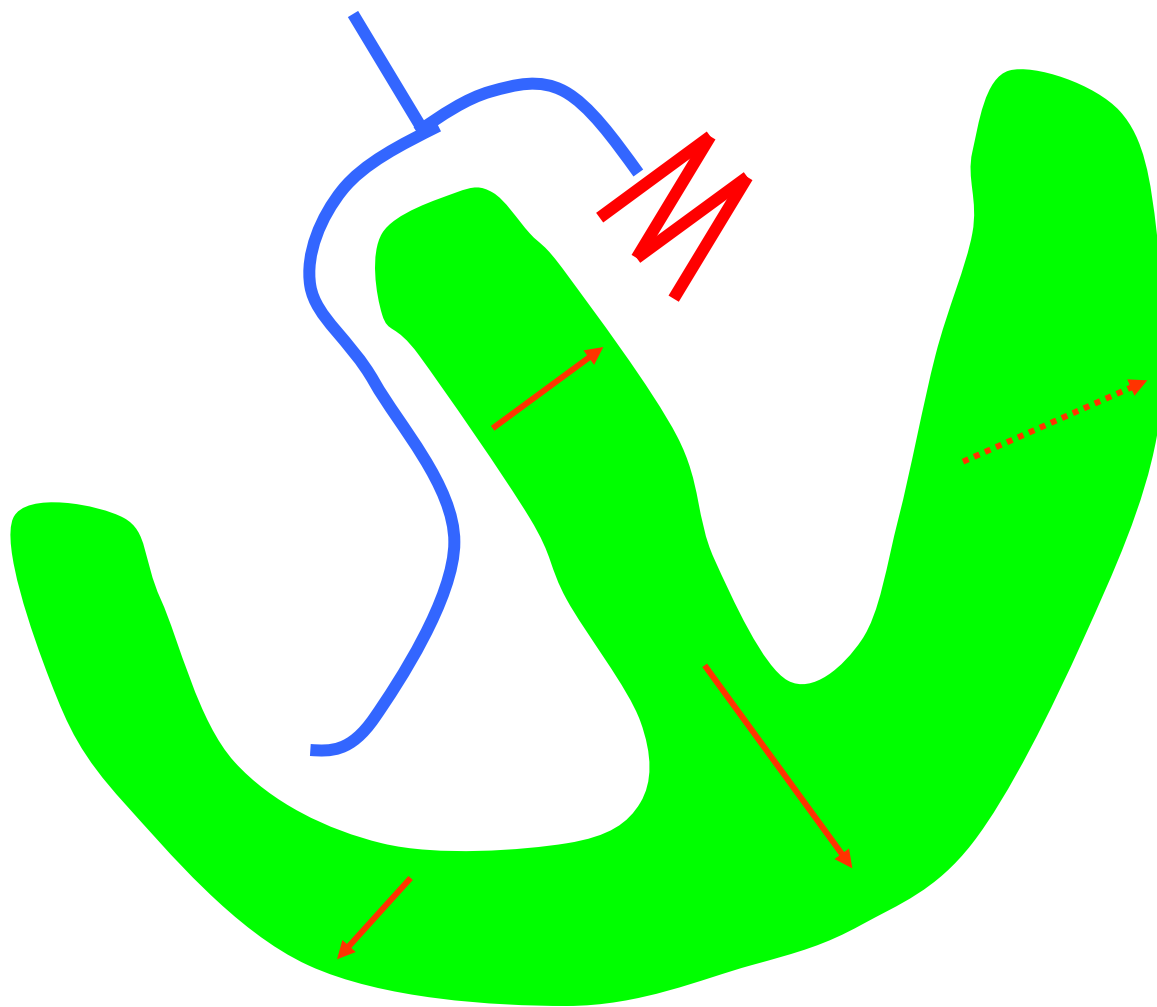
- RBBB is seen in :-
 - (1) occasional normal subjects
 - (2) pulmonary embolus
 - (3) coronary artery disease
 - (4) ASD
 - (5) active carditis
 - (6) RV diastolic overload

Partial / Incomplete RBBB

- is diagnosed when the pattern of RBBB is present but the duration of the QRS does not exceed 0.12 seconds.

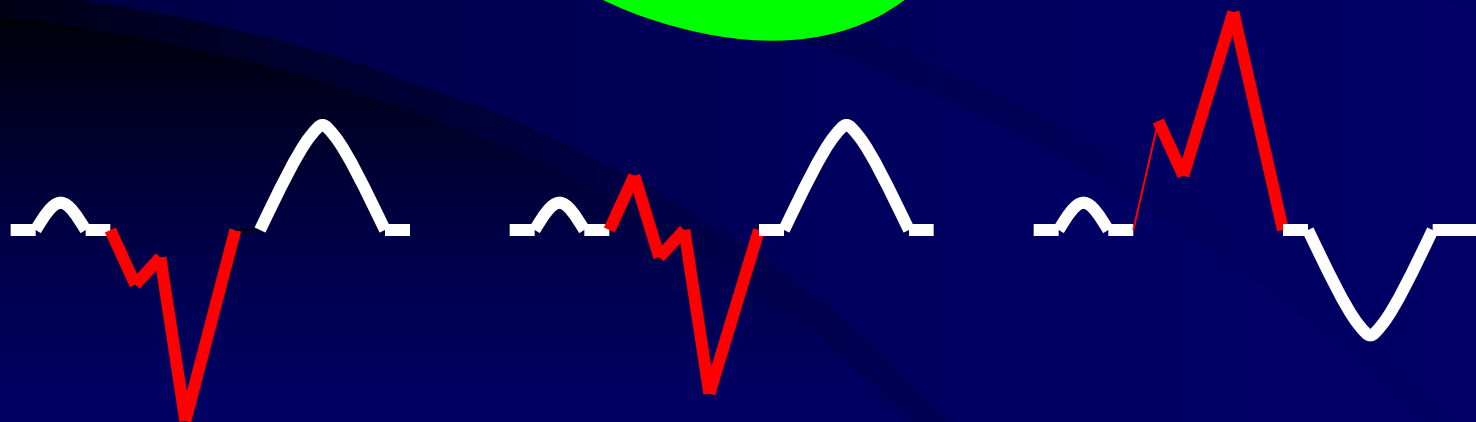

Left Bundle Branch Block

- In LBBB the left ventricle is activated from the right bundle.



Phases of Activation

- Impulse passes to the left of the septum below the block (1a) at the same time as the paraseptal region. (1b)
- Activation of the RV follows (small magnitude). (2)
- Finally delayed activation of the LV which is slow due to conduction through normal myocardium. (3)



ECG criteria for LBBB

- (1) Prolonged QRS complexes, greater than 0.12 seconds
- (2) Wide, notched QRS (M shaped) I, AVL, V5, V6
- (3) Wide, notched QS complexes are seen in V1 (due to spread of activation away from the electrode through septum + LV)
- (4) In V2, V3 small r wave is seen due to activation of paraseptal region

LBBB & MI

- MI should not be diagnosed in the presence of LBBB → Q waves are masked by LBBB pattern.

Significance of LBBB

- LBBB is seen in :-

(1) Always indicative of organic heart disease

(2) Found in ischaemic heart disease

(3) Found in hypertension.

Partial / Incomplete LBBB

- is diagnosed when the pattern of LBBB is present but the duration of the QRS does not exceed 0.12 seconds.

Summary

- BBB - delay/block in either of the bundle branches
- RBBB - RSR in V1
- LBBB - 'W' shape in V1, 'M' shape in V6
- Cannot diagnose the presence of MI with LBBB